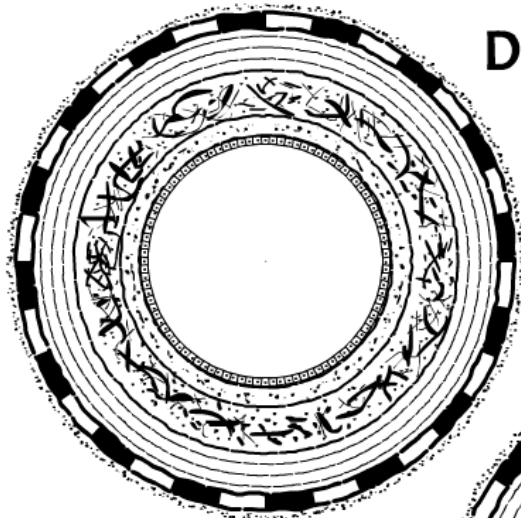
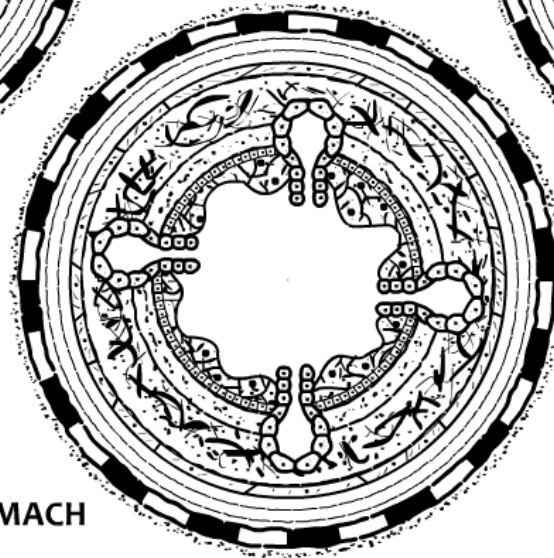


DIGESTIVE LAYERS

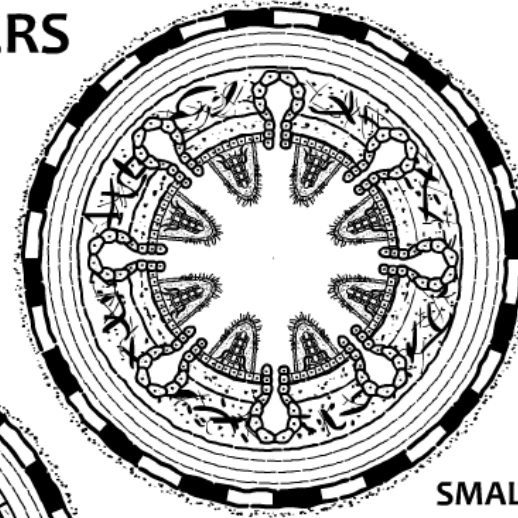
www.zerobio.com



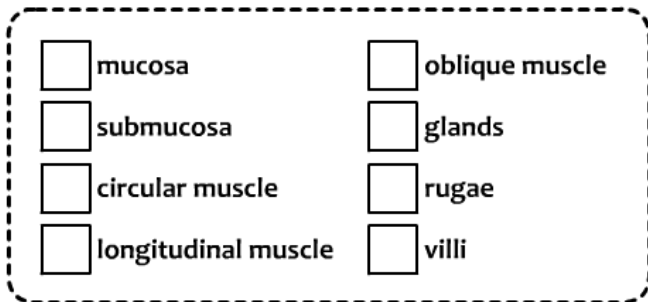
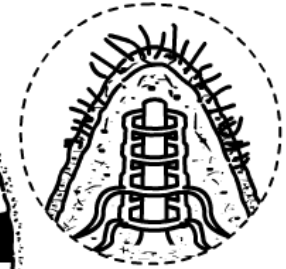
ESOPHAGUS



STOMACH



SMALL INTESTINE



ADDITIONAL NOTES:

- The circular, longitudinal and oblique muscle (in the stomach) make up one overall layer that is collectively called the “**muscularis**”.
- There is also a thin covering layer on the outside of each organ called the “**serosa**”.
- The open space/cavity in the middle of the organ is called the “**lumen**”.